

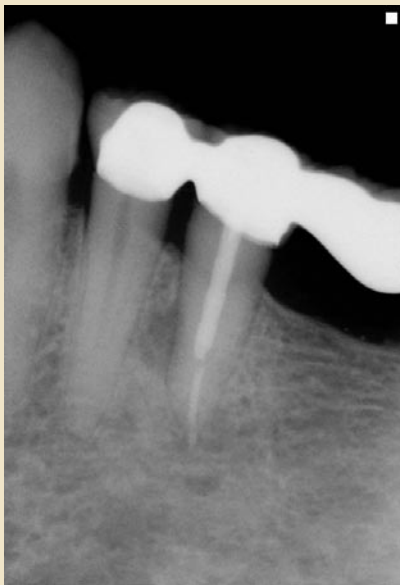

Dr. Brian Hornberger  
*presents*

# Case of the Month

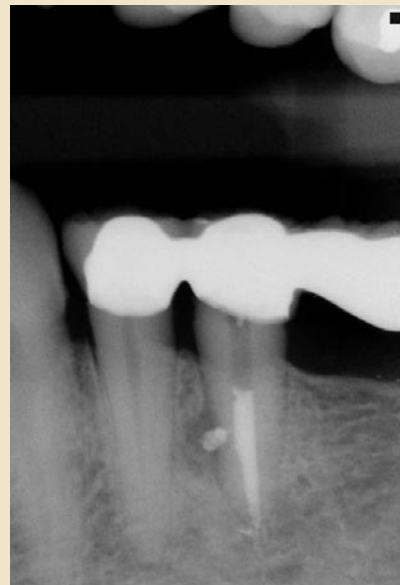
April 2011

*Before*



This patient was referred for a failing endodontically treated tooth #20. Note the presence of a lateral radiolucency present at the depth of the post placement. This is a clue indicating either an unsealed lateral canal or root fracture.

*After*



A decision to endodontically re-treat #20 was made. Post removal was needed to access the canal space. Thorough cleansing/shaping and copious irrigation allowed for sealing of a lateral canal through thermal compaction of gutta-percha and sealer.



*Creating happy patients with experience & skill*

3801 Lone Tree Way | Antioch, CA 94509  
Phone: (925) 753-5810 | [www.eastcountyendo.com](http://www.eastcountyendo.com)