



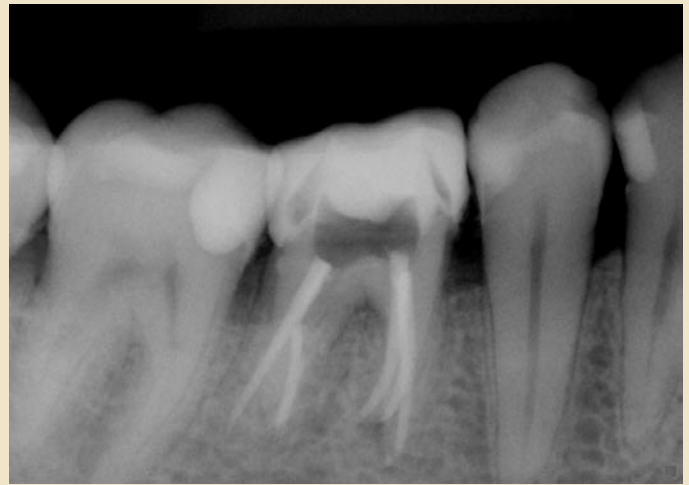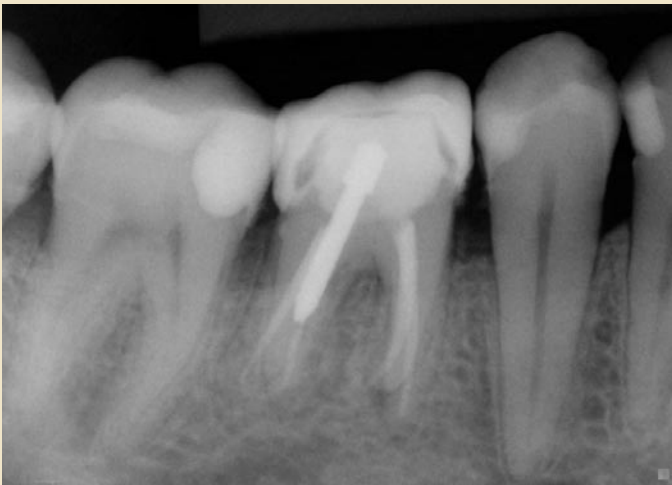
Dr. Brian Hornberger
presents

Case of the Month

March 2011

Before

After



This patient was referred by his general dentist with a chief complaint of acute pain in tooth #30. This tooth had a previous history of endodontic treatment six years earlier. Radiographic exam revealed the previous treatment to appear satisfactory, however, there was a small radiolucency noted at the apex of the mesial root.

A decision to endodontically re-treat #30 was made. Post removal was needed to access the distal canal spaces. All canals were re-treated and enlarged apically. During re-treatment, a third and completely separate mesial canal was located, cleaned and sealed. The patient has remained asymptomatic since treatment.



Creating happy patients with experience & skill

3801 Lone Tree Way | Antioch, CA 94509
Phone: (925) 753-5810 | www.eastcountyendo.com