

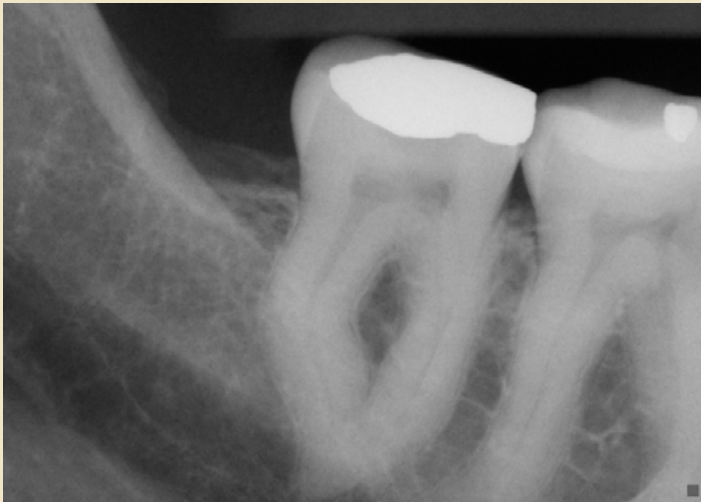


Dr. Brian Hornberger
presents

Case of the Month

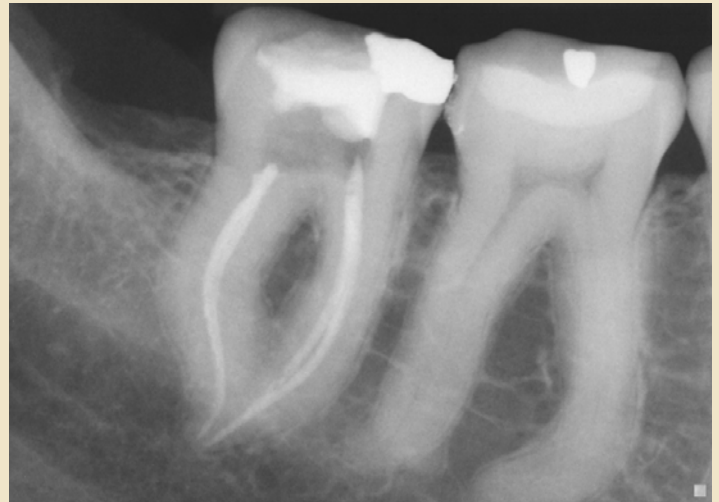April 2010

Before



"Fused root" Lower Molars with "S" shaped curvature can present the practitioner with complicated anatomy.

After



The root lengths on all canals here measured 25mm each. This required delicate yet deliberate instrumentation and filling techniques to achieve ideal results.



Creating happy patients with experience & skill

3801 Lone Tree Way | Antioch, CA 94509
Phone: (925) 753-5810 | www.eastcountyendo.com